



Clinico-microbiological and Risk Factor Analysis of *Strongyloides stercoralis* Infections in South India

*Abirami lakshmy Jayachandran, Vandhitha Muralidharan, Balan Kandasamy

Department of Microbiology, Karpaga Vinayaga Institute of Medical Sciences and Research Center, Chengalpet, Tamil Nadu India.

*Email: drabi3285@gmail.com

DOI: 10.31964/mltj.v9i2.529

Abstract: *Strongyloides stercoralis* is a soil-transmitted nematode infection. It is implicated in causing hyper infection syndrome in immunosuppressed patients. This infection can also present without symptoms. The study aims to analyze the demographic data and risk factors associated with acquiring this infection and detect *Strongyloides stercoralis* in the stool sample by microscopy and modified agar plate culture. Combining microscopy and culture can facilitate detecting the infection in cases of low worm burden. Evaluation of socio-demographic information and risk factors will help in implementing control measures. A total of 986 stool samples were received. All the samples were examined by saline and Iodine mount examination. All the stool samples were cultured by the modified agar plate method. The risk factors, patient demographic details and clinical features were analyzed for significant association using the Chi-square test and a p-value < 0.05 was considered significant) by quick calls graph pad software. The overall prevalence of *Strongyloides stercoralis* infection was 22(1.23%), and all these cases were diagnosed on stool examination by the demonstration of rhabditiform larva of *Strongyloides stercoralis* and adult females by modified agar plate culture. The positivity for *Strongyloides* larva was high among males, patients from rural areas and individuals working in agricultural settings. There was a significant association between walking barefoot and the demonstration of the larva. Patients presenting from endemic regions, even with vague, nonspecific gastrointestinal symptoms, especially with risk factors like Diabetes mellitus, should be screened for this infection and treated. Awareness, proper hygiene practices, and appropriate treatment are necessary to prevent this soil-transmitted helminthic infection.

Keywords: Neglected infection; rhabditiform larva; soil-transmitted nematodes.

INTRODUCTION

Strongyloides stercoralis is one of the soil-transmitted nematode infections seen in African and Southeast Asian countries, with an estimated prevalence of more than 100 million cases (Buonfrate D et al., 2020). The infections in immunocompetent individuals can be asymptomatic or nonspecific and can present as disseminated or hyper infection syndrome in immunosuppressed patients and can be fatal. The chronicity of this infection is attributed to its life cycle (Buonfrate D et al., 2020). Soil-transmitted nematode infections are frequently documented in poor sanitary and hygienic conditions (Ulaganeethi et al., 2023).

The prevalence of Strongyloidiasis ranges from 8.5% to 33% per various studies (Devi et al., 2011; Valerioa et al., 2013; Bisoffi et al., 2013; Krolewiecki et al., 2019). Strongyloidiasis is an underestimated and overlooked parasitic infection (Valerioa et al., 2013; Bisoffi et al., 2013). In Immunocompetent individuals, they can

present with symptoms after many years of acquiring the infection due to the persistence of the parasite, which can often lead to a delay in diagnosis (Buonfrate D et al., 2020; Munisankar et al., 2022). Ivermectin treats *Strongyloides stercoralis* infections (Devi et al., 2011). Stool examination, Harada mori filter paper technique, serological tests and polymerase chain reaction methods are available for diagnosing this soil-transmitted helminth, each diagnostic modality has advantages and disadvantages (Bisoffi et al., 2013; Khanna et al., 2015). In most diagnostic microbiology labs, only saline/Iodine mount examination by microscopy will be performed. Not suspecting strongyloidiasis due to non-awareness of the symptoms and risk factors can delay the detection and initiation of treatment for this infection. Though few studies have evaluated the risk factors and symptomatology in general for soil-transmitted nematodes, the present study aims to analyze the socio-demographic information and significance of association between various risk factors along with the identification of *Strongyloides stercoralis* larva by microscopic examination and modified agar plate method—a Lactophenol cotton blue stain stained the mount prepared from saline in agar plate culture.

MATERIALS AND METHODS

Over two years June 2016 to June 2018, all the stool samples received in the Department of Microbiology, Karpaga Vinayaka Institute of medical sciences and research centre, Chengalpet, Tamil Nadu, India, were included in the study. The institutional ethical committee approved the study (ref: IEC KIMS/2016/03). All the stool samples were received in a container with a spatula with a bar code. After receiving the samples in the laboratory, the examination was done by saline wet mount and Iodine mount (Khanna et al., 2015; Keiser et al., 2004; Jongsuksuntigul et al., 2003). All the stool samples were also cultured by modified agar plate method for identifying the *Strongyloides* larva and female worm.(Khanna et al., 2015; Keiser et al., 2004).

The Modified Agar Plate Method

A canal of 1 cm is cut surrounding an agar block in the centre of a nutrient agar plate (Himedia Chennai India) with the help of a surgical blade and filled up with normal saline. The nutrient agar plate comprises peptone (5 gm/L), yeast extract (1.5 gm/L), HM peptone B 1.5 gm/L (equivalent to beef extract), agar(15 gm/L) and sodium chloride (5 gm/L).In the present study single stool specimen was obtained. With the help of an applicator, stick stool material is collected from the formed stool. In the case of watery stool/diarrheagenic stool, the material is selected from areas with mucus.

A stool sample is applied to the central part of the agar. The plate is sealed with parafilm and placed at room temperature, 25°C, in the dark. After 2 to 3 days, the sealed plate is examined for larval tracks and motile larvae. After about three days, at the top portion of the lid of the Petri plate, a hole is made with hot rod/forceps that melt the plastic, and 1 ml of 10% formalin is added to the canal filled with normal saline. After the addition of formalin, the contents of the canal were pipetted out and examined under a light microscope (Olympus CH20i) initially under 10X magnification for screening, followed by 40 X (Khanna et al., 2015; Keiser et al., 2004; Jongsuksuntigul et al., 2003).

The general demographic information like age group, place of stay: rural/urban, educational status (completed High school, Bachelor's degree/ Master's degree/ illiterate), occupation: employed, Employed in agricultural setup/nonagricultural setup) were also documented. The patient's other risk factors like comorbid illnesses, history of walking barefoot, and symptomatic/Asymptomatic status were analyzed for the

significant association by Chi-square test (p-value < 0.05 was considered significant) by quick calls graph pad software.

RESULTS AND DISCUSSION

An overall 986 stool samples were received and analyzed. Of these, 12 (1.21%) were identified as Rhabditiform larva *Strongyloides stercoralis* by the saline wet mount. The larva of *S. stercoralis* was differentiated from the hookworm larva by a short buccal cavity and double bulb oesophagus (Figure 1). The overall prevalence of soil-transmitted nematodes was 53 (5.37%). Other than *Strongyloides stercoralis* larvae 12 (22.6%) ova of other helminths like hookworm 32 (60.37%), *Ascaris lumbricoides* 6 (11.3%), *Enterobius vermicularis* 2 (3.77%), *Trichuris trichiuria* 1 (1.88%) was also reported.

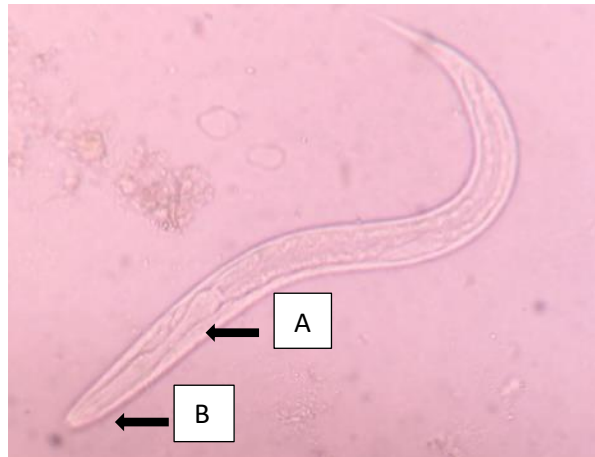

Figure 1. Rhabditiform Larva *Strongyloides stercoralis* by Saline Wet Mount.
A: Double bulb esophagus, B: Short buccal cavity

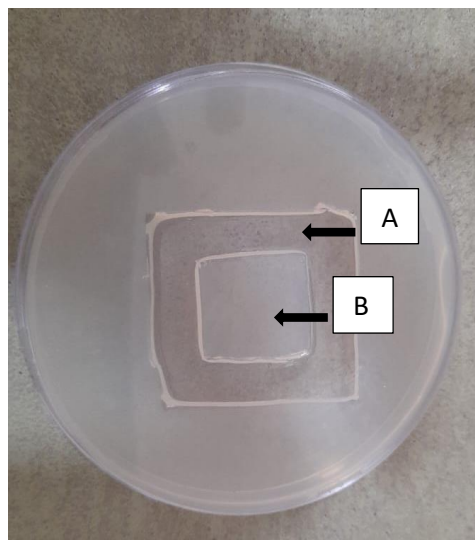


Figure 2. Modified Agar Plate Culture Method-Agar Block in the Centre with a Surrounding Canal of 1 cm Size in a Nutrient Agar Plate.
A: 1 cm canal is made around the agar block, B: Agar block

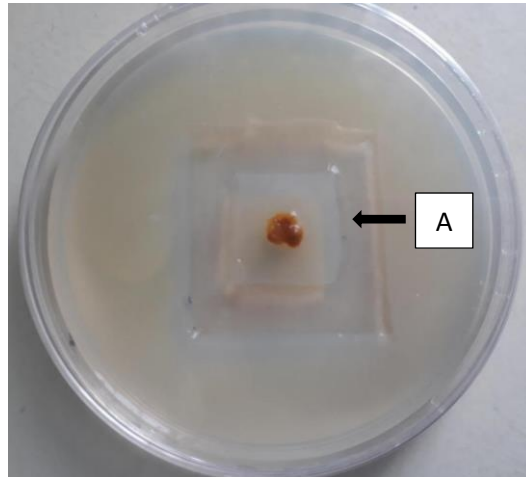


Figure 3. Modified Agar Plate Culture Method-Stool Sample Surrounded by Saline in the Canal in Nutrient Agar Plate. A: Saline is added around the agar block, and a stool sample is placed on the agar block.

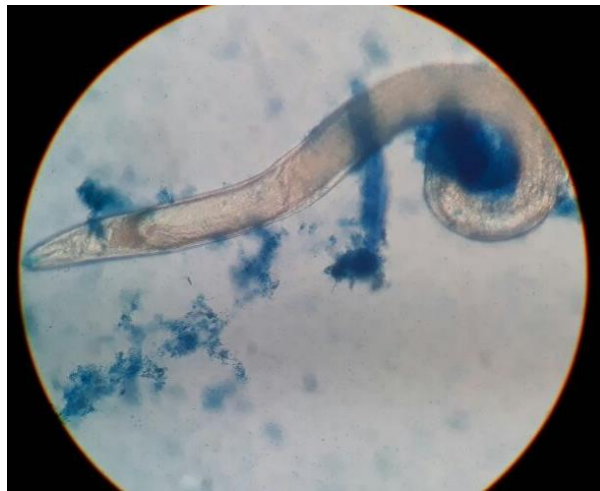

Figure 4. Female Adult Worm of *Strongyloides stercoralis* in Lactophenol Cotton Blue Mount.

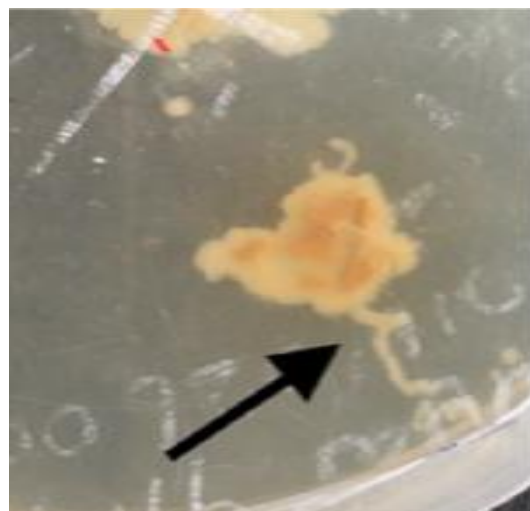


Figure 5. Larval Tracks Observed on the Surface of Agar

The stool samples were cultured by modified agar culture (Khanna et al., 2015). Larva and Adult female worms of *Strongyloides stercoralis* were demonstrated from the wet mount of the fluid from the canal stained by Lactophenol cotton blue after incubation at room temperature in the dark for 2 to 3 days (Figure 2,3,4). Larval tracks were also observed (Figure 5). The demographic details were analyzed (Table 1). The positivity for *Strongyloides stercoralis* larva was high among males 8(66%), patients from rural areas 9(75%), and individuals working in an agricultural setup 7(58.3%). On analysis of the following risk factors like symptoms, comorbid-comorbid illness, gender, and walking barefoot, the association between the history of walking barefoot in the outdoor environment was significantly associated with *Strongyloides* infection (Table 2).

Table 1. Socio-Demographic Data

Parameter N=986	Number (%)	Presence of <i>Strongyloides stercoralis</i> larva n=12. Number (%)
Age distribution		
20 to 30	383 (38.8%)	1(8.33%)
31 to 40	327(33.1%)	6(50%)
41 to 50	154(15.6%)	3(25%)
51 to 60	122 (12.3%)	2(16.6%)
Total	986	12
Gender		
Male	622 (63%)	8(66%)
Female	364(36.9%)	4(33%0
Total	986	12
Locality		
Rural	652(66.1%)	9(75%)
Urban	334(33.8%)	3(25%)
Total	986	12
Education		
Higher secondary school education	358(36.3%)	3(25%)
Bachelor degree	496(50.3%)	6(50%)
Master degree	132(13.3%)	3(25%)
Total	986	12
Occupation		
Employed in agricultural setup	456(46.2%)	7(58.3%)
Employed in a nonagricultural setup	530(53.7%)	5(41.6%)
Total	986	12

Strongyloidiasis is one of the most commonly overlooked nematode infections; chronic infection can be symptomatic. In the present study, the various symptoms presented by the patients with *Strongyloides* larva were acute diarrhea, abdominal pain, vomiting and melena, similar to other the study (Kaminsky RL et al.,2016; Dada-Adegbola HO et al.,2010). Research by Kaminsky RL et al. shows that 87.5% of the patients presented with epigastric pain, anemia, and diarrhea. *Strongyloides* can

present with nonspecific manifestations like itching, diarrhea, constipation and dry cough (Pulmonary involvement) (Keiser et al.,2004).

Table 2. Analysis of Risk Factors and Clinical Presentation

Parameter n=986	Presence of Larva	Absence of Larva	P value*
Symptomatic patients (Gastrointestinal)			
Presence of symptoms n=243	2	241	0.740
Absence of symptoms n=743	10	733	
General Master health checkup			
Presence of symptoms n=518	4	514	0.246
Absence of symptoms n=468	8	460	
History of walking barefoot in an outdoor environment			
History of walking barefoot in outdoor environment. n=136	7	129	0.0004*
No History of walking barefoot in an outdoor environment. n=850	5	845	
Comorbid illness (Diabetes, Tuberculosis, Liver diseases)			
Presence of comorbid illness. n=186	4	182	0.255
Absence of comorbid illness. n=800	8	792	
Gender			
Male n=622	8	614	1.000
Female n=364	4	360	
Usage of open field for defaecation			
Usage of open field for defaecation n=23	0	23	1.000
Non Usage of open field for defaecation n=963	12	951	

Chi square test *p value < 0.05- significant

Four patients had associated illnesses like diabetes mellitus, cirrhosis of the liver and pulmonary tuberculosis (Table 2) similar to other research (Marques et al., 2010; Chordia et al., 2011; Tebib et al., 2013; Dada-Adegbola HO et al., 2010; Jongwutiwes U et al., 2014). Though there are associations between specific risk factors like low socioeconomic status, male gender, alcoholism and *Strongyloides*, as documented by Keiser et al. (2004), Dada-Adegbola HO et al. (2010), in the present study, there was only a significant association with the history of walking barefoot. The predominance of the male gender (Table 1) could be due to their outdoor work and hence the higher probability of exposure to *Strongyloides stercoralis* infective stages similar to the study by Jongsuksuntigul et al. (2003).

Different diagnostic modalities are available for detecting this infection, like stool examination, Kato Katz technique, Harada mori filter paper technique, ELISA and PCR (Buonfrate D et al., 2013). In the current study, we have performed a modified agar plate culture method by Khanna et al., and we demonstrated the larva and adult worm. In cases of very low worm burden, a single examination of stool specimens may lead to missing the detection of the parasites, and repeated examination might be necessary. The agar plate technique can be beneficial in early diagnosis in such scenarios. Though Eosinophil counts are expected to be raised in parasitic infections, as reported by (González et al.,2010), in the present study, elevated Eosinophil counts were not observed. Evaluation of Strongyloidiasis should be done as a routine investigation to detect larvae in patients with certain comorbid conditions since the infection can persist for many years in the untreated host through repetitive auto-infective cycles. This chronic infection will also lead to anemia, poor cognition and growth and can affect performance at school for young children (Buonfrate D et al., 2020).

Though in a study by Ghoshal et al. (2012), 86.6% of the patients were diagnosed with strongyloidiasis by first stool microscopy examination, based on it is difficult to diagnose if the parasite load is low and requires repeated examinations. Repeated stool examinations and culture techniques like modified agar plates will facilitate diagnosing such situations. The limitation of the present study is that the serological tests for detecting seroprevalence and molecular tests were not performed.

CONCLUSION

Detection of *Strongyloides* larva by direct stool microscopy and culture for demonstrating the adult worm should also be considered in individuals with nonspecific symptoms, particularly in endemic regions. Asymptomatic individuals should also be treated without appropriate therapy; infections persist throughout life. The current study had a significant association between barefoot walking and strongyloidiasis. Hence health education and improved sanitation are also essential, along with specific treatment with ivermectin to eradicate this neglected parasitic infection.

CONFLICT OF INTEREST

The Authors declare no conflict of interest.

FUNDING

The Authors received no external funding.

REFERENCES

- Bisoffi, Z., Buonfrate, D., Montresor, A., Requena-Méndez, A., Muños, J., Krolewiecki A.J., Gotuzzo, E., Mena, M.A., Chiodini, P.L., Anselmi, M., Moreira, J., & Albonico, M. (2013). *Strongyloides stercoralis* a plea for action. *PLoS Negl Trop Dis*, 7(5), e2214. Doi: 10.1371/journal.and.0002214.
- Buonfrate D., Requena-Mendez, A., Angheben, A., Munoz, J., Gobbi, F., Van Den Ende J., & Bisoffi, Z. (2013). Severe strongyloidiasis: a systematic review of case reports. *BMC Infect Dis*, 8(13), 78. doi 10.1186/1471-2334-13-78.
- Buonfrate D., Bisanzio, D., Giorli, G., Odermatt, P., Fürst, T., Greenaway, C., French, M., Reithinger, R., Gobbi, F., Montresor, A., & Bisoffi, Z. (2020). The Global Prevalence of *Strongyloides stercoralis* Infection. *Pathogens*, 9(6), 468. doi 10.3390/pathogens9060468.

- Chordia, P., Christopher, S., Abraham, O.C., Muliyl, J., Kang, G., & Ajjampur, S.S. (2011). Risk factors for acquiring *Strongyloides stercoralis* infection among patients attending a tertiary hospital in south India. *Indian J Med Microbiol*, 29(2), 147-151. doi 10.4103/0255-0857.81797.
- Dada-Adegbola, HO., Oluwatoba, OA., & Bakare, RA. (2010). Strongyloidiasis: prevalence, risk factors, clinical and laboratory features among diarrhea patients in Ibadan Nigeria. *Afr J Med Med Sci*, 39(4), 285-292. PMID: 21735994.
- Devi, U., Borkakoty, B., & Mahanta, J. (2011). Strongyloidiasis in Assam, India: A community-based study. *Trop Parasitol*,1(1):30-32. Doi: 10.4103/2229-5070.72110.
- Ghoshal, U., Khanduja, S., Chaudhury, N., Gangwar. D., & Ghoshal ,U.C. (2012).A series on intestinal strongyloidiasis in immunocompetent and immunocompromised hosts. *Tropical gastroenterology*, 33(2),135-139. <http://dx.doi.org/10.7869/tg.2012.31>
- González, A., Gallo, M., Valls, M.E., Muñoz, J., Puyol, L., Pinazo, M.J, Mas, J., & Gascon, J. (2010). Clinical and epidemiological features of 33 imported *Strongyloides stercoralis* infections. *Trans R Soc Trop Med Hyg*, 104(9), 613-616. Doi: 10.1016/j.trstmh.2010.06.001.
- Jongsuksuntigul, P., Intapan, P.M., Wongsaroj, T., Nilpan, S., Singthong, S., Veerakul, S., & Maleewong, W. (2003). Prevalence of *Strongyloides stercoralis* infection in northeastern Thailand (agar plate culture detection). *J Med Assoc Thai*, 86(8), 737-41. PMID: 12948272
- Jongwutiwes, U., Waywa, D., Silpasakorn, S., Wanachiwanawin, D., & Suputtamongkol, Y. (2014). Prevalence and risk factors of acquiring *Strongyloides stercoralis* infection among patients attending a tertiary hospital in Thailand. *Pathog Glob Health*,108(3), 137-40. doi 10.1179/2047773214Y.0000000134.
- Kaminsky, RL., Reyes-García, SZ., & Zambrano, LI. (2016). Unsuspected *Strongyloides stercoralis* infection in hospital patients with comorbidity needs proper management. *BMC Infect Dis*, 29(16):98. doi 10.1186/s12879-016-1424-3.11.
- Keiser, P.B., & Nutman, T.B. (2004). *Strongyloides stercoralis* in the immunocompromised population. *Clin Microbiol Rev*, 17(1), 208-217. doi 10.1128/CMR.17.1.208-217.2004.
- Khanna, V., Tilak, K., & Prakash, P.Y. (2015). Modified agar culture method for *Strongyloides stercoralis*. *Trop Parasitol*, 5(2), 136-138. Doi: 10.4103/2229-5070.162535
- Krolewiecki, A., & Nutman, T.B. (2019). Strongyloidiasis: A Neglected Tropical Disease. *Infec Dis Clin North Am*, 33(1),135–151. <https://doi.org/10.1016/j.idc.2018.10.006> PMID: 30712758
- Marques, C.C., Da Penha Zago-Gomes, M., Gonçalves, C.S.,& Pereira, F.E. (2010). Alcoholism and *Strongyloides stercoralis*: Daily ethanol ingestion positively correlates with the frequency of *Strongyloides* larvae in the stools. *PLoS Negl Trop Dis*, 4(6), e717. Doi: 10.1371/journal.and.0000717
- Munisankar, S., Rajamanickam, A., Balasubramanian, S., Muthusamy, S., Dolla, C.K., Menon, P.A., Chinnayan, P., Whalen, C., Gumne, P., Kaur ,I., Nadimpalli, .V., Deverakonda, A., Chen, Z., David Otto, J., Habitegiyorgis, T., Kandaswamy, H., Nutman, T.B., & Babu, S. (2022). Seroprevalence of *Strongyloides stercoralis* infection in a South Indian adult population. *PLoS Negl Trop Dis*, 16(7), e0010561. Doi: 10.1371/journal.and.0010561

- Tebib, N., Tebib, N., Paredes, M., Castro, R., Baggio S., Torrico, M..V, Leon., AAF, Zamorano, M.H., Chappuis, F., & Getaz ,L. (2023). Prevalence and risk factors of *Strongyloides stercoralis* in hemodialysis in Cochabamba, Bolivia: a cross-sectional study. *BMC Nephrol*, 24(1), 27. doi: 10.1186/s12882-023-03074-9
- Ulaganeethi, R., Saya, G.K., Rajkumari, N., Kumar, S.S., Ganapathy, K., & Dorairajan, G. (2023) Soil-Transmitted Helminth Infections among Antenatal Women in Primary Care Settings in Southern India: Prevalence, Associated Factors and Effect of Anti-Helminthic Treatment. *Trop. Med. Infect. Dis*, (48), 1-12. <https://doi.org/10.3390/tropicalmed8010048>
- Valerioa, L., Rourea, S., Fernández-Rivasb, G., Basile ,L., Martínez-Cuevas, O., Ballesteros, ÁL., Ramos, X., & Sabrià, M. (2013). *Strongyloides stercoralis*, the hidden worm. Epidemiological and clinical characteristics of 70 cases diagnosed in the North Metropolitan Area of Barcelona, Spain, 2003-2012. *Trans R Soc Trop Med Hyg*, 107(8), 465-470. doi 10.1093/truth/trt053.